

# Journal of Biomedical Optics

[SPIEDigitalLibrary.org/jbo](http://SPIEDigitalLibrary.org/jbo)

## **Integrated flexible handheld probe for imaging and evaluation of iridocorneal angle**

Vengalathunadakal K. Shinoj  
Vadakke Matham Murukeshan  
Mani Baskaran  
Tin Aung

# Integrated flexible handheld probe for imaging and evaluation of iridocorneal angle

Vengalathunadakal K. Shinoj,<sup>a,b</sup> Vadakke Matham Murukeshan,<sup>a,\*</sup> Mani Baskaran,<sup>b</sup> and Tin Aung<sup>b</sup>

<sup>a</sup>Nanyang Technological University, School of Mechanical and Aerospace Engineering, Center for Optical and Laser Engineering, Singapore 639798, Singapore

<sup>b</sup>Singapore Eye Research Institute (SERI) and Singapore National Eye Center (SNEC), 11 Third Hospital Avenue, Singapore 168751, Singapore

**Abstract.** An imaging probe is designed and developed by integrating a miniaturized charge-coupled diode camera and light-emitting diode light source, which enables evaluation of the iridocorneal region inside the eye. The efficiency of the prototype probe instrument is illustrated initially by using not only eye models, but also samples such as pig eye. The proposed methodology and developed scheme are expected to find potential application in iridocorneal angle documentation, glaucoma diagnosis, and follow-up management procedures. © 2015 Society of Photo-Optical Instrumentation Engineers (SPIE) [DOI: 10.1117/1.JBO.20.1.016014]

Keywords: anterior segment ocular imaging; glaucoma; trabecular meshwork; iridocorneal angle.

Paper 140704R received Oct. 28, 2014; accepted for publication Dec. 17, 2014; published online Jan. 16, 2015.

## 1 Introduction

The irreversible and progressive nature of the disease makes glaucoma one of the serious ophthalmic diseases.<sup>1,2</sup> Primary angle closure glaucoma (PACG) is one form of glaucoma where the eye's drainage canals become blocked by the iris so that the intraocular pressure rises over time.<sup>3,4</sup> PACG is a major form of glaucoma in Asia and, in contrast to western countries, it responsible for the majority of bilateral blindness in Singapore, China, and India.<sup>5,6</sup> Optical imaging methods have been vital in the area of biomedical imaging for various disease diagnoses.<sup>7–10</sup>

Documentation of the entire angle is needed to identify abnormalities or the status of iridocorneal angle. Most of the current imaging methods based on optical coherence tomography (OCT) are either cross-sectional or expensive and are not extensively used by clinicians.<sup>11,12</sup> Pentacam, based on Scheimpflug's photography principle, can be used to image the anterior chamber through its circumference, where the imaging of an obliquely tilted object can be accomplished with a maximum depth of focus and the least image distortion under given conditions.<sup>13,14</sup> However, the assessment of the iridocorneal angle cannot be done in detail using this method, since direct visualization of the angle recess is not available due to the limitations of visible light penetrating the necessary depth. The main pathology in PACG is a closed anterior chamber angle which is diagnosed clinically using gonioscopy, an instrument that uses a mirror system.<sup>15,16</sup> Gonioscopy is a subjective procedure and the documentation is mainly through various grading procedures.<sup>15–17</sup> The main drawback with this method is patient discomfort and physician compliance.<sup>18</sup> It was reported earlier that 50% of physicians do not perform gonioscopy in clinical examination as it is cumbersome and requires time-consuming methods.<sup>19</sup> Interpretation of gonioscopic findings requires expertise and is subject to substantial disagreement between physicians,<sup>20</sup> in spite of the technique

being low cost and simple to use. Multiple reflections from the lens or mirrors used along with the coupling gel cause the quality of the image to be poor. In spite of all this, gonioscopy remains the clinical reference standard as it allows the clinician to observe the angle structures through a cheaper instrument in the clinic and to make note of pathological findings of clinical importance.

Photographic-based documentation allows the eye care clinician to document and refer to the earlier images for abnormalities in the anterior segment of the eye and angle.<sup>21</sup> The RetCam™ was primarily designed for wide-field retinal imaging in children to document premature retinal growth in a condition called “retinopathy of prematurity.”<sup>22</sup> Later, it was modified to document the anterior chamber angle in the form of EyeCam™.<sup>23,24</sup> However, imaging of the anterior chamber angle using EyeCam™ takes longer than gonioscopy (about 5 to 10 min per eye) and the device is more expensive compared with gonioscopy. We have recently demonstrated a gel-assisted imaging technology for angle imaging—an exclusive wide angle imaging probe which is nonbulky and inexpensive. The probe can be attached to a slit lamp, providing the flexibility to be used by a nontechnical person.<sup>25</sup>

In this context, we propose a miniaturized integrated charge-coupled diode (CCD) camera and light-emitting diode (LED) light source-based probe system, which enables evaluation of the iridocorneal region inside the eye. Full details of the probe configuration and methodology are given in the following sections.

## 2 Materials and Method

### 2.1 Preparation of Sample

One randomly selected eye from four pigs (*Sus scrofa domestica*) was enucleated from the local abattoir and used within 6 h of death. The *ex vivo* samples were transported on ice to the laboratory to maintain their “freshness.” Each sample was fixed onto a custom eye holder, which was mounted on a

\*Address all correspondence to: Vadakke Matham Murukeshan, E-mail: mmurukeshan@ntu.edu.sg

translation stage with micrometer accuracy. Extraocular tissues, such as the conjunctiva and lacrimal gland, were removed from the samples.

## 2.2 Imaging System

The distal end to support the optics is designed in a CAD design software (SolidWorks, USA) and built as a separate module. The probe distal end that houses one micro-CCD conduit and four illumination channels has a diameter of 26 mm, which is suitable for compactness and easy handling, with a sufficient working distance from the eye. The center channel has an internal diameter of 3 mm and is meant for a 3 mm × 3 mm micro-CCD video camera (IntroSpicio™ 115, Medigus Ltd., Israel), which is employed as the image capturing device. The video camera system is used together with a light source. The distal end also has four channel slots of internal diameter 5 mm for LED illumination purposes that are drilled at an angle of 71 deg surrounding the camera slot, so as to provide adequate illumination across the field of view (FOV) of the micro-CCD. The LEDs have a viewing angle of 20 deg. The slot angle and viewing angle of LEDs are such that the focus area of the camera has adequate illumination at the iridocorneal area for image capture. The microcamera head is connected to a camera controller (video processor unit of IntroSpicio™ 115, Medigus Ltd.) that controls the video signal from and to the camera head by a cable. The camera controller can control brightness/contrast, gain, white balance, etc., of the video signal. The main input to the device is 100 to 240 AC (autoswitching). The micro-CCD has 291,000 effective numbers of pixels (500 horizontal × 582 vertical) with an FOV of 140 deg. Figure 1 illustrates the photograph of the assembled probe, and the probe distal end is shown in the inset.

## 2.3 Equipment Safety and Maintenance

The imaging probe fulfils safety directions in routine clinical use as per international standards. According to the International Commission on Non-ionizing Radiation Protection, no evaluation for retinal hazard is required if the visible light has a luminance of less than 10,000 candela/m<sup>2</sup>.<sup>26</sup> The LED sources, such




Fig. 1 Photograph of imaging system (inset: probe distal end).

as the one used in our study (maximum luminous intensity of 7000 mcd), have a smaller degree of spatial coherence compared with laser light sources and this leads to a distribution of light over a relatively larger area making it well within the maximum permissible limit. The cleaning and maintenance of the probe include customary chemicals such as 4% sodium hypochlorite solution for rinsing or 75% isopropyl alcohol wipes for cleaning the tip of the camera lens. Thus, it does not require specialized cleaning solutions or protocol.

## 2.4 Imaging Method

The imaging scheme is illustrated schematically in Fig. 2. The imaging device comprises an eye imaging probe having a central axis and a corneal contact surface. An imaging sensor is located at the central axis of the probe and has variable resolution at different depths which is configured for capturing the interior of the eye when the contact surface is placed at the cornea or at the limbus of the eye through a coupling gel. The four LEDs' viewing angles and slot angles are designed such that the illumination region optimally covers the targeted iridocorneal angle region and provides the required illumination throughout the region. The LEDs are positioned based on a Lambertian approach to illuminate the targeted area in a controlled manner. To be precise, the uniform distribution of the light emitted by the source (the combination of LEDs) has the same brightness or luminescence when viewed from any angle. Further, the brightness of the LEDs can be controlled using a potentiometer. The probe and sensors are connected via a flexible connection (with flexible wires) to the camera controller. The camera controller in turn is connected to a personal computer using an S-video connector for display and/or for storage in a media storage device.

## 3 Results and Discussion

The functionality of the imaging probe prototype is tested first on an ocular imaging eye model (OEMI-7, Ocular Instruments Inc., Bellevue, Washington). Figure 3(a) shows the photograph of the eye model. The imaging probe is placed near the limbal region of the cornea to image the opposite iridocorneal angle. With the use of a coupling gel (e.g., Vidisic gel, Bausch & Lomb, New York), the micro-CCD camera can visualize

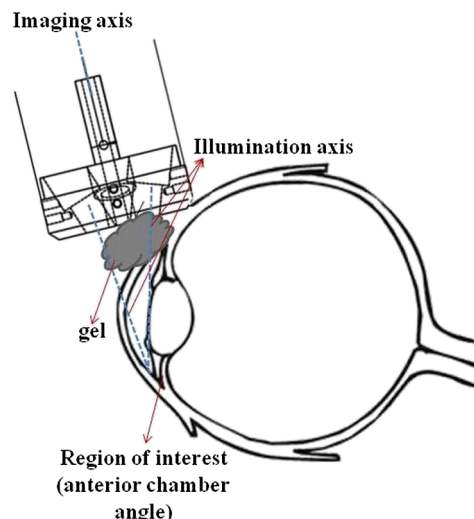



Fig. 2 Illustration of the imaging method.





**Fig. 3** (a) Ocular eye model; (b) and (c) images of two opposite quadrants of the model eye, and the red arrows highlight the iridocorneal angle region.

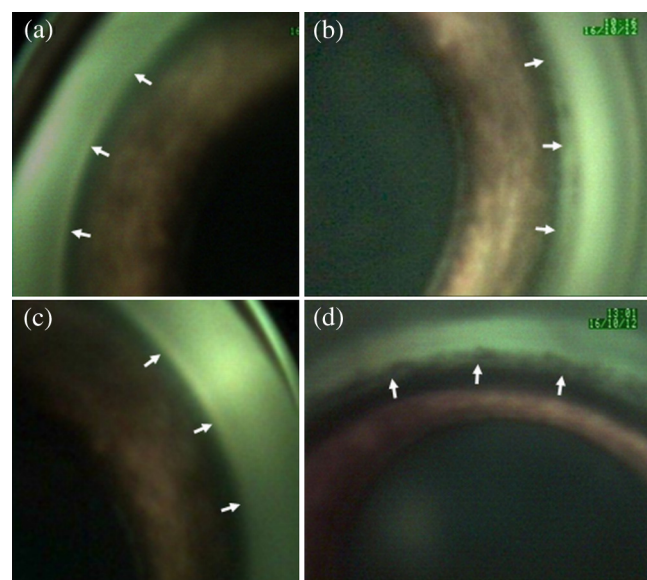
structures in the anterior segment in a manner similar to direct gonioscopy. The coupling gel provides an optical interface between the camera's lens and the cornea and eliminates the total internal reflection that naturally occurs at the corneal tear film-air interface, thus allowing rays of light coming from the iridocorneal angle to escape into the microcamera. Users have the options to capture still images or to record video stream from which images can be extracted at a later stage. The obtained results of the two opposite quadrants of the model eye are shown in Figs. 3(b) and 3(c). The opposite iridocorneal angle and the simulated trabecular meshwork of the eye model are visible in the images and are highlighted using red arrows.

In our experiment, the sample used is pig eye due to its resemblance to the features observed in human eyes. It is more easily available compared with those of nonhuman primates. Also, a pig eye is similar in size to the human eye,  $\approx 22$  mm in length compared with 24 mm in humans. Pig eye has been used in vision science research involving, but not limited to, glaucoma and corneal transplant studies.<sup>27,28</sup> The pig eyes are obtained from a local abattoir immediately after the animal's death. Imaging of the anterior chamber is carried out after fixing the eye on a support. Imaging is performed on four different sides of the eye to have a complete view of the angle region inside eye since the camera's FOV is 140 deg. The obtained results from four sides of pig eye are shown in Figs. 4(a)–4(d).

Even though Pentacam allows very easy, fast, and noncontact quantification of the anterior chamber parameters, the evaluation of the iridocorneal angle cannot be done in detail since direct visualization of the angle recess is not available. Gonioscopy still remains the clinical reference standard as it allows the clinician to observe the angle structures in the clinic and to make note of the pathological findings of clinical importance. In Eyecam<sup>TM</sup>-based angle assessment, fluid-based optical coupling avoids additional pressure exertion on the cornea as in gonioscopy and hence eliminates the concern for compression artifacts. However, the device is more expensive than gonioscopy and extra space is needed for supine examination that may widen the angle due to the effect of gravity. Devices based on anterior segment optical coherence tomography (AS-OCT) technology can obtain cross-sectional images in the sitting position and provide better resolution of the anterior chamber angle; however, a panoramic view is not available for complete evaluation and documentation of devices placed in the

angle.<sup>29</sup> With our proposed device, angle images can be carried out in a sitting position. The angle measurement for all four quadrants can be carried out in less than 2 min. No personnel expertise is required for the assessment. This device is easily portable, nonbulky, can be attached to a slit lamp, and can be connected to any desktop/laptop PC installed with the interfacing software. Table 1 compares the key features of our proposed device with that of other complimentary devices used for anterior chamber angle imaging.

The clinical application of such an imaging probe is gaining more importance in the context not just of the documentation of the iridocorneal angle findings in angle closure disease, but also in preoperatively assessing and documenting the “openness” of the iridocorneal angle during microinvasive glaucoma surgeries (MIGS) such as various stent procedures and in gonio-synechiolysis. There is a growing trend of letting such MIGS devices to reside in contact with the anterior chamber angle, and there are possibilities of long-term migration or erosion of these devices.<sup>30</sup> It is only prudent to have a good documentation of the position of these devices and the changes in the surrounding iridocorneal angle. The above described imaging probe can be



**Fig. 4** (a)–(d) Angle images (from four different sides) of the porcine pig eye sample obtained using the developed probe (white arrows highlight the iridocorneal angle region).

**Table 1** The comparison of our device parameters with other complementary imaging techniques.

Device/technology	Ease of use	Panoramic view	Clinical interpretation	Cost
Pentacam	Noncontact/sitting	Yes	Difficult	High
EyeCam	Contact/supine	Yes	Easy	High
AS-OCT	Noncontact/sitting	No	Difficult	High
Proposed device in this manuscript	Contact/sitting	Yes	Easy	Low

an objective alternative for clinician documented evidence in clinical practice, especially in an increasingly medicolegal environment. Further, such a device can be used vis-à-vis variable corneal diameters of animals for the iridocorneal angle and anterior segment documentation, whereas a fixed type of gonioslens restricts such use.<sup>31</sup>

## 4 Conclusion

A handheld ocular imaging probe system is designed, developed, and illustrated to continuously display, capture, and record images of anterior segment and iridocorneal angle regions. The system and methodology are validated using an eye model and pig eyes as test samples. This instrument, which can give good quality digital images, can be a cheaper alternative to gonioscopy-based angle detection schemes. Further, the illustrated handheld probe can also be used in the management of glaucoma for monitoring landmark identification during device implantation procedures.

## Acknowledgments

The authors acknowledge the financial support received through NMRC (NIG09nov001) and A\*STAR-SERC grant (No. 112 148 0003). The authors have filed a patent (PAT/118/14/14/SG PRV) on the design aspect and imaging methodology of the probe scheme described in this manuscript.

## References

- P. C. Van Veldhuisen et al., "The Advanced Glaucoma Intervention Study (AGIS): 7. The relationship between control of intraocular pressure and visual field deterioration," *Am. J. Ophthalmol.* **130**(4), 429–440 (2000).
- W. M. Grant and J. F. Burke Jr., "Why do some people go blind from glaucoma?," *Ophthalmology* **89**(9), 991–998 (1982).
- E. M. Stone et al., "Identification of a gene that causes primary open angle glaucoma," *Science* **275**(5300), 668–670 (1997).
- W. P. Nolan et al., "Detection of primary angle closure using anterior segment optical coherence tomography in Asian eyes," *Ophthalmology* **114**(1), 33–39 (2007).
- S. K. Seah et al., "Incidence of acute primary angle-closure glaucoma in Singapore: an island-wide survey," *Arch. Ophthalmol.* **115**(11), 1436–1440 (1997).
- T. Aung et al., "Anterior chamber depth and the risk of primary angle closure in 2 East Asian populations," *Arch. Ophthalmol.* **123**(4), 527–532 (2005).

- V. M. Murukeshan, V. K. Shinoj, P. Saraswathi, and P. Padmanabhan, "Diagnostic sensing of specific protein in breast cancer cells using hollow-core photonic crystal fiber," in *Multimodality Breast Imaging: Diagnosis and Treatment*, E. Y. K. Ng, U. Rajendra Acharya, Rangaraj M. Rangayyan, and Jasjit S. Suri, Eds., pp. 475–495, SPIE Press, Bellingham, Washington (2013).
- V. K. Shinoj and V. M. Murukeshan, "Hollow-core photonic crystal fiber based multifunctional optical system for trapping, position sensing, and detection of fluorescent particles," *Opt. Lett.* **37**(10), 1607–1609 (2012).
- J. James, V. M. Murukeshan, and L. S. Woh, "Integrated photoacoustic, ultrasound and fluorescence platform for diagnostic medical imaging—proof of concept study with a tissue mimicking phantom," *Biomed. Opt. Express* **5**(7), 2135–2144 (2014).
- J. G. Fujimoto, "Optical coherence tomography for ultrahigh resolution in vivo imaging," *Nat. Biotechnol.* **21**(11), 1361–1367 (2003).
- M. E. Nongpiur et al., "Classification algorithms based on anterior segment optical coherence tomography measurements for detection of angle closure," *Ophthalmology* **120**(1), 48–54 (2013).
- S. Radhakrishnan et al., "Real-time optical coherence tomography of the anterior segment at 1310 nm," *Arch. Ophthalmol.* **119**(8), 1179–1185 (2001).
- T. Scheimpflug, "Improved method and apparatus for the systematic alteration or distortion of plane pictures and images by means of lenses and mirrors for photography and for other purposes," GB Patent 1196 (1904).
- R. Jain and S. Grewal, "Pentacam: principle and clinical applications," *J. Curr. Glaucoma Pract.* **3**(2), 20–32 (2009).
- L. M. Sakata et al., "Comparison of gonioscopy and anterior segment ocular coherence tomography in detecting angle closure in different quadrants of the anterior chamber angle," *Ophthalmology* **115**(5), 769–774 (2008).
- H. G. Scheie, "Width and pigmentation of the angle of the anterior chamber: a system of grading by gonioscopy," *AMA Arch. Ophthalmol.* **58**(4), 510–512 (1957).
- N. G. Congdon et al., "A proposed simple method for measurement in the anterior chamber angle: biometric gonioscopy," *Ophthalmology* **106**(11), 2161–2167 (1999).
- D. T. Quek et al., "Angle imaging: advances and challenges," *Indian J. Ophthalmol.* **59**(7), S69–S75 (2011).
- A. L. Coleman, F. Yu, and S. J. Evans, "Use of gonioscopy in medicare beneficiaries before glaucoma surgery," *J. Glaucoma* **15**(6), 486–493 (2006).
- M. Baskaran et al., "Comparison of EyeCam and anterior segment optical coherence tomography in detecting angle closure," *Acta Ophthalmol.* **90**(8), e621–e625 (2012).
- M. Datiles et al., "Clinical evaluation of cataracts," *Duane's Clin. Ophthalmol.* **1**, 1–20 (1992).
- C. Wu, R. A. Petersen, and D. K. VanderVeen, "RetCam imaging for retinopathy of prematurity screening," *J. Am. Assoc. Pediatr. Ophthalmol. Strabismus* **10**(2), 107–111 (2006).
- S. A. Perera et al., "Use of EyeCam for imaging the anterior chamber angle," *Invest. Ophthalmol. Visual Sci.* **51**(6), 2993–2997 (2010).
- M. Baskaran et al., "Angle assessment by EyeCam, goniophotography, and gonioscopy," *J. Glaucoma* **21**(7), 493–497 (2012).
- V. K. Shinoj et al., "Note: A gel based imaging technique of the iridocorneal angle for evaluation of angle-closure glaucoma," *Rev. Sci. Instrum.* **85**(6), 066105 (2014).
- ICNIRP, "Guidelines on limits of exposure to broad-band incoherent optical radiation (0.38 to 3 μm)," *Health Phys.* **73**(3), 539–554 (1997).
- J. Ruiz-Ederra et al., "The pig eye as a novel model of glaucoma," *Exp. Eye Res.* **81**(5), 561–569 (2005).
- C. Faber et al., "Orthotopic porcine corneal xenotransplantation using a human graft," *Acta Ophthalmol.* **87**(8), 917–919 (2009).
- H.-T. Wong et al., "High-definition optical coherence tomography imaging of the iridocorneal angle of the eye," *Arch. Ophthalmol.* **127**(3), 256–260 (2009).
- L. V. M. Brandão and M. C. Grieshaber, "Update on minimally invasive glaucoma surgery (MIGS) and new implants," *J. Ophthalmol.* **2013**, 705915 (2013).

31. R. S. Smith, D. Korb, and S. W. John, "A gonioscope for clinical monitoring of the mouse iridocorneal angle and optic nerve," *Mol. Vis.* **8**, 26–31 (2002).

**Vengalathunadakal K. Shinoj** is currently engaged at the Centre for Optical and Laser Engineering (COLE), Nanyang Technological University (NTU), Singapore, as a research fellow. He was awarded a PhD degree from NTU, Singapore, in 2012. His research focuses on design and development of an improved imaging probe for ocular imaging targeting angle-closure glaucoma diagnosis. His research findings have been published in many internationally recognized peer-reviewed journals and presented in various prestigious international conferences.

**Vadakke Matham Murukeshan** has been with the School of Mechanical and Aerospace Engineering, Nanyang Technological University (NTU), Singapore, since 1997. He leads a research group that focuses on nanoscale optics, biomedical optics, and optical metrology. He has published over 250 international journal and conference proceedings papers, 6 book chapters, 6 patents, and 8 innovation disclosures. Currently, he is the deputy director

of the Center for Optical and Laser Engineering (COLE) of NTU, Singapore.

**Mani Baskaran** is a senior clinical research fellow at SERI and assistant professor at the Office of Clinical Sciences, Duke-NUS Graduate Medical School, Singapore. His current research interests include imaging, diagnosis, and management of angle closure in Asia; and developing novel devices, software algorithms in anterior segment imaging with engineering faculty across, Singapore. He has published more than 110 international publications, 8 book chapters, and 6 copatents in the field of glaucoma.

**Tin Aung** is a senior consultant and head of glaucoma service at the, Singapore National Eye Centre, deputy director of the Singapore Eye Research Institute, and a professor in the Department of Ophthalmology at the National University of Singapore. He obtained his MBBS and master's degrees in medicine from the National University of Singapore. He obtained the fellowships of the Royal College of Surgeons of Edinburgh and the Royal College of Ophthalmologists in 1997 and a PhD degree in molecular genetics from University College London, UK, in 2004.